

Original Article

Renal transplantation in adults with thrombotic thrombocytopenic purpura/haemolytic–uraemic syndrome

P. J. Conlon¹, D. C. Brennan³, W. W. Pfaf⁴, W. F. Finn⁵, T. Gehr⁶, R. Randal Bollinger² and S. R. Smith¹

¹Department of Medicine, ²Department of Surgery, Duke University Medical Center, Durham, NC, USA; ³Department of Medicine, Washington University Medical Center, St Louis, MO; ⁴Department of Surgery, University of Florida, Gainesville, FL; ⁵Department of Medicine, University of North Carolina at Chapel Hill, NC; ⁶Department of Nephrology, Medical College of Virginia, Richmond, VA

Abstract

Background. Thrombotic thrombocytopenic purpura/haemolytic–uraemic syndrome (TTP/HUS) is a rare cause of renal failure in adults. There is little data concerning the outcome of adult patients who receive a renal transplant for TTP/HUS.

Methods. We have carried out a survey of 22 transplant centres in the USA to determine the outcome of patients who developed ESRD from TTP/HUS and latter received a renal transplant.

Results. Twelve of the 22 centres responded to our inquiry. Seven centres had not transplanted any patients with TTP/HUS, and five centres had transplanted a total of 24 grafts in 17 patients with TTP/HUS. Thirty-three per cent of patients demonstrated definite clinical and pathological evidence of recurrence of TTP/HUS. An additional 16% of patients demonstrated pathological evidence of possible recurrence of TTP/HUS in the absence of clinical manifestations. The overall 1-year graft survival rate was 42% and the 2-year graft survival rate was 35%. In our experience recurrence TTP/HUS was associated with universal graft failure. Although cyclosporin A does occasionally cause a thrombotic angiopathy in patients with no history of TTP/HUS, we found no evidence that it should be avoided in patients with a previous history of ESRD from TTP/HUS who subsequently receive a renal transplant.

Conclusions. TTP/HUS frequently recurs in adults who receive a renal transplant, with a 2-year graft survival rate of 35%.

Introduction

In 1925 Eli Moschowitz reported a case of ‘an acute febrile pleomorphic anemia with thrombosis of the terminal arterioles and capillaries’ [1]. This syndrome

subsequently became known as thrombotic thrombocytopenic purpura (TTP) and is characterized by the development of neurological disease in association with a microangiopathic haemolytic anaemia. Thirty years later Gasser reported an illness occurring in children characterized by microangiopathic haemolytic anaemia in association with acute renal failure, which became known as the haemolytic–uraemic syndrome [2]. In adults it is often clinically impossible to differentiate these two conditions, as patients with HUS and TTP have varying degrees of neurological and renal involvement. Consequently, in adults, these two terms refer to different manifestations of what is now considered to be a single pathological process, referred to herein as thrombotic thrombocytopenic purpura/haemolytic–uraemic syndrome (TTP/HUS) [3].

While TTP/HUS is the most common cause of acute renal failure in young children [4], it is a rare disease in adults, with an estimated frequency of one case per million per year [5]. The prognosis of TTP/HUS has improved dramatically in the last 20 years in association with the use of plasmapheresis [6]. We have previously reported on the renal prognosis in patients with TTP/HUS [7]. In that study of 68 adults with idiopathic TTP/HUS, seven patients (10%) required dialysis and renal function eventually recovered in five of these.

The outcome of renal transplantation in children with TTP/HUS has been reported by a number of authors [8–13]. The results of renal transplantation in adults with TTP/HUS are less well documented. The pathophysiology of TTP/HUS may be different in older patients, as TTP/HUS in adults is only rarely associated with verocytotoxin-producing *Escherichia coli*. We therefore sought to define the prognosis for adults with ESRD from this rare disease who receive a renal transplant.

Subjects and methods

In January 1994 we mailed a questionnaire to 22 renal transplant centres in the USA asking them to return to us

Correspondence and offprint requests to: Peter J. Conlon, MB, DUMC Box 3014, Durham, NC 27710, USA.

clinical data pertaining to adult patients (age greater than 18 years) with TTP/HUS as the cause of renal failure who had received a cadaveric or living related renal transplant at their centre during the previous 15 years. A diagnosis of TTP/HUS was dependent on the presence of at least four of the following criteria in the absence of any other underlying disease: (1) platelet count less than $90\,000/\text{mm}^3$; (2) haemolytic anaemia with a haemoglobin less than 10 g/dl, and schistocytes on a peripheral blood smear with a negative Coombs' test; (3) evidence of neurological disease; (4) renal involvement manifested by either a serum creatinine (Cr) at presentation of greater than 1.4 mg/dl or an abnormal urine sediment; and (5) fever of 38°C or greater. In order to avoid a selection bias, each centre was asked to submit data on all patients from that centre with TTP/HUS as a cause of renal failure who had received a renal transplant over the specified 15 year period of time, regardless of outcome.

The outcome of renal transplantation was classified according to Hebert *et al.* [14]. Group 1 patients had both clinical and histological evidence of recurrence of TTP/HUS in the post-transplant period, and were thus deemed to have definite recurrence of TTP/HUS. Group 2 consisted of patients with histological features consistent with TTP/HUS, but lacked some of the clinical features consistent with TTP/HUS listed above and were thus considered to have possible recurrence of TTP/HUS; group 3 consisted of patients with neither clinical nor histological features of TTP/HUS and were considered not to have recurrent disease. Histopathological evidence included the presence of glomerular fibrin thrombi and double contours of capillary loops, with or without arteriolar fibrin thrombi.

A variety of immunosuppressive protocols were employed including azathioprine and steroids alone; azathioprine, steroids and OKT3; and 'triple' therapy with cyclosporin A (CsA), azathioprine, and prednisone.

Results

Twelve of the 22 centres responded to our enquiry. Seven centres had not transplanted any patients with TTP/HUS and five had transplanted 24 kidneys into 17 patients (range 1–5 kidneys). Thirteen patients received a single kidney, three patients received two grafts, and one patient received five kidney transplants.

The mean age of presentation of TTP/HUS was 29 ± 11 (\pm SD) years. Thirteen patients were female and 16 were white. The mean Cr, haematocrit and platelet count at initial presentation were respectively 10 ± 6.5 mg/dl, $20.1 \pm 8.6\%$, and 76 ± 39 ($\times 10^3/\text{cc}$). All patients became dialysis dependent after their initial illness and had been maintained on dialysis for a mean of 29 ± 35 months prior to receiving their first renal transplant.

Three patients died in the early postoperative period (within 90 days). Forty-two per cent of grafts were functioning at 1 year and 35% (Figure 1) at 2 years (range in survival of grafts was from 2 days to 13 years).

Eight patients developed definite clinical and pathological evidence of recurrence of TTP/HUS (group 1) within 2 weeks of renal transplantation with associated thrombocytopenia, schistocytes on peripheral blood smear, haemolysis, fever, and transplant dysfunction (Figure 2). Each of these demonstrated glomerular

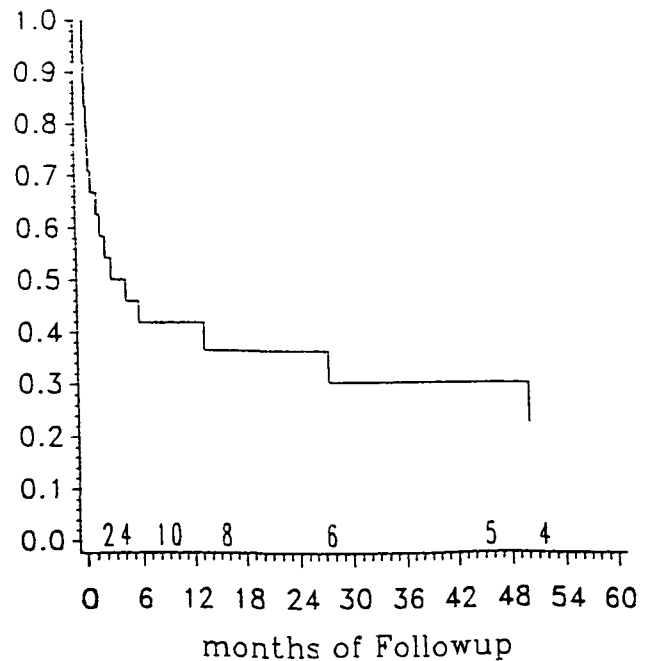


Fig. 1. Kaplan-Meier curve for graft survival in patients with TTP/HUS.

congestion and endothelial oedema with thrombi within glomerular capillary loops in association with hyaline changes in smaller vessels and intraluminal thrombosis in larger vessels. Five of these patients were begun on a course of plasma exchange and the remaining three were treated with intravenous fresh frozen plasma. All eight patients rapidly lost their renal transplant and underwent graft nephrectomy.

A further four patients demonstrated some pathological evidence of recurrence of TTP/HUS without other clinical manifestations of recurrence (group 2). Two grafts were lost within 2 weeks of transplant in patients with no clinical evidence of haemolysis or thrombocytopenia, but with some histological features compatible with recurrent TTP/HUS (group 2), namely intraluminal thrombi in small and medium-sized vessels, associated with endothelial reactivity and infiltration with fibrin and without much interstitial infiltration with lymphocytes. Two other grafts were lost (at 13 years and 4 months) which had no clinical evidence of recurrent TTP/HUS. Renal transplant biopsy in both of these cases had marked changes of interstitial fibrosis and tubular atrophy (group 2), findings that were compatible with chronic rejection. In addition, however, there were some intervascular thrombi and endothelial reactivity which may have been due to recurrent TTP/HUS.

The remaining 12 grafts had no evidence of recurrence of HUS/TTP (group 3). Five of these grafts continue to function a mean of 3 years after transplantation. One graft was lost to histologically confirmed acute cellular rejection which was unresponsive to OKT3 therapy without clinical or histological evidence of TTP/HUS. Two patients died post-transplant,

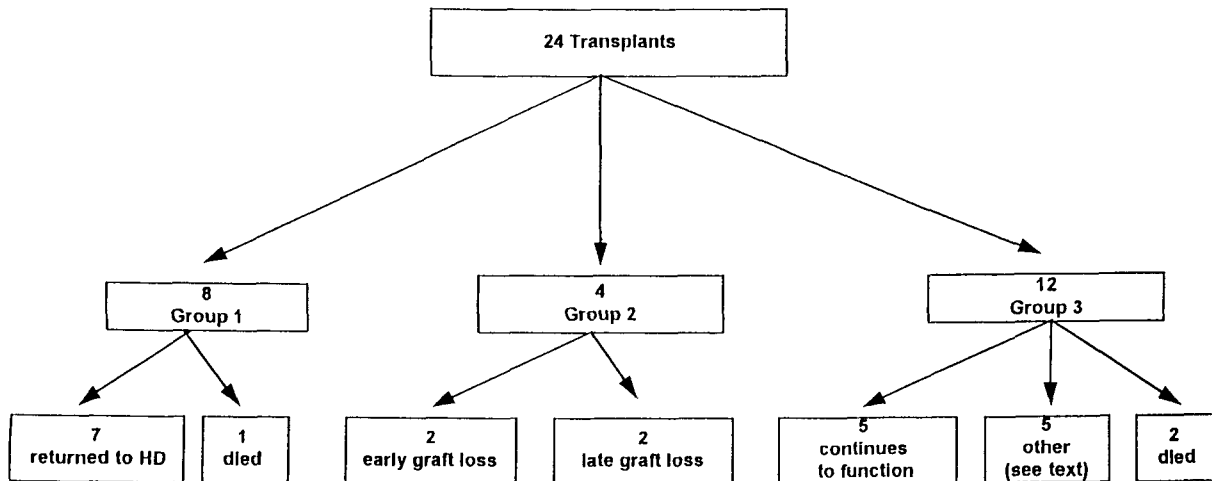


Fig. 2. Outcome of transplants in TTP/HUS. Group 1, definite recurrence; group 2, possible recurrence; group 3, no evidence of recurrence.

one from a myocardial infarction and one from cytomegalovirus infection. One graft demonstrated slowly progressive renal dysfunction which on renal biopsy demonstrated cryoglobulins in the subendothelial space.

Four patients in this series underwent more than one transplant. One patient received five renal transplants all of which rapidly failed with recurrence of TTP/HUS. One patient developed clinical and pathological evidence of recurrent TTP/HUS within 1 month of transplantation in both grafts requiring graft nephrectomy. The other two patients both did well. One patient's first graft lasted 13 years and was lost to chronic rejection but did have some evidence of endothelial reactivity, and fibrin thrombi in vessels (group 2). It is now 12 months since her second cadaveric transplant and she has no clinical or pathological evidence of recurrent HUS/TTP. The third patient developed transplant failure after 4 years, secondary to chronic rejection, and is now three years into his second graft with a serum Cr of 1.8 mg/dl.

Five grafts were from living related donors, one of which continues to function. One patient developed fulminant CMV infection; one failed secondary to early recurrence of TTP/HUS; and two failed secondary to chronic rejection. Graft failure occurred in 11 of 13 cases in which CsA-based immunosuppression was used, and in nine of 11 cases in which CsA was not used. There was no significant difference in the mean time to graft failure or in the frequency of development of recurrent TTP/HUS between patients receiving and not receiving CsA. There did not appear to be any relationship between the length of time on dialysis prior to transplantation and the probability of recurrence of TTP/HUS.

Discussion

The recurrence of TTP/HUS after renal transplantation in children has been reported by a number of

authors [8–13,15], with the rate of recurrence being between 0% and 41% [9,10,15]. The pathophysiology of TTP/HUS in children is frequently different than that of adults in that TTP/HUS in children is frequently induced by verocytotoxin-producing bacteria with associated diarrhoea [16], while this is uncommon in adults, we hypothesized that the prognosis of adults and children with TTP/HUS who receive a renal transplant may be different.

In this series collected from five centres in the United States, using a variety of immunosuppressive protocols, 12.5% of the patients died following renal transplantation, one-third demonstrated definite evidence of recurrence of TTP/HUS and only 35% of patients have a functioning graft 2 years after renal transplantation.

Five of the renal transplants in this series were in one patient, all of which failed. This large proportion of grafts given to a single patient skews the data somewhat. When the data was analysed with these five grafts excluded the 1-year graft survival rate was 42% and the 2-year graft survival rate was 36%.

The differential diagnosis of a thrombotic angiopathy following renal transplantation can frequently be difficult as vascular rejection, CsA toxicity and *de novo* thrombotic angiopathy can all produce a similar clinical and pathological manifestation [17]. Additionally cytomegalovirus, the most common viral pathogen after renal transplantation, has been associated with TTP/HUS [18]. In this series 33% of patients had definite clinical and pathological evidence of recurrent TTP/HUS and an additional 17% demonstrated pathological changes in the grafts which were compatible with either recurrent TTP/HUS and/or chronic rejection. It is particularly difficult to distinguish vascular rejection from recurrent TTP/HUS. However, an incidence of four of 24 grafts failing secondary to vascular rejection would be much higher than is generally expected. Pathologically it is impossible to make the distinction.

We have been uniformly unsuccessful in aborting the microangiopathic process in patients who

developed recurrent TTP/HUS post-transplant, despite various treatments including steroids, plasma infusion and plasma exchange [6,18,19]. Given the poor renal prognosis associated with definite recurrence as defined here, patients who develop recurrent TTP/HUS with acute renal transplant failure who do not respond early to intravenous IgG or plasma exchange plasma infusion are probably best treated with early transplant nephrectomy. Based on this small series we believe that patients who develop early transplant failure secondary to recurrent TTP/HUS are at high risk of developing TTP/HUS in subsequent grafts. Based on these poor results of renal transplantation in patients with TTP/HUS as the cause of renal failure, it is now our practice not to perform live related transplantation on such patients; we will, however, after discussion of our experience, offer them cadaveric renal transplantation.

The pathophysiology of thrombotic angiopathy following renal transplantation is multifactorial, and many of the commonly used immunosuppressive agents have been implicated including CsA, azathioprine, OKT3, and FK506 [13,18,20–25]. It has been suggested that azathioprine immunosuppression may avoid some of these problems. Our data do not support this notion.

Cytomegalovirus infection has been associated with post-transplant thrombotic microangiopathy [18]. In this series we have observed serious CMV infection which contributed to the patient's death in two cases, and less severe CMV infection in two other patients. Two of these four patients had clinical evidence of thrombotic microangiopathy (recurrence of TTP/HUS) at the time CMV infection was diagnosed.

There are several theories as to the possible pathogenesis of thrombotic microangiopathy. In children, *Escherichia coli* has been shown to produce a toxin which can damage the endothelium and induce the microangiopathic process. In cases of TTP/HUS not associated with diarrhoea, a number of other theories have been advanced. These include: (1) decreased production of endothelial cell prostaglandin I₂ (PGI₂) or excessive lability of PGI₂ from a deficiency of PGI₂-stimulating or stabilizing factor present in normal plasma; (2) defective fibrinolysis from inadequate production of endothelial cell plasminogen activator; (3) the presence of a substance capable of promoting intravascular platelet clumping; and (4) abnormal metabolism of von Willibrand factor multimers leading to increased platelet aggregation [26]. It is unclear how renal transplantation should impact on these phenomena to induce recurrence of TTP/HUS.

In summary, the 2-year graft survival rate for 24 renal transplants performed at five centres in recipients with TTP/HUS as the underlying cause of ESRD was 35%.

Definite evidence of recurrence of TTP/HUS was present in 33% of the overall group, and histological evidence of recurrence in the absence of the overt clinical syndrome of TTP/HUS was present in an additional 16% of these transplanted patients. Patients

who develop early recurrence of TTP/HUS in a renal transplant are at high risk of recurrent TTP/HUS in subsequent grafts. This information needs to be taken into account in considering patients with ESRD secondary to TTP/HUS for renal transplantation.

References

- Moschowitz E. An acute pleomorphic anemia with hyaline thrombosis of the terminal arterioles and capillaries: a hitherto undescribed disease. *Arch Intern Med* 1925; 36: 89–93
- Gasser C, Gauter E, Speck A, Siebermann RE, Oechslin R. Haemolytisch-Uraemische syndrome: bilaterale Nierenrindennekrosen bei akuten erworbenen haemolytischen Anamien. *Schweiz Med Wochenschr* 1955; 85: 905–909
- Remuzzi G, HUS and TTP: variable expression of a single entity. *Kidney Int* 1987; 32: 292–308
- Milford DV, Taylor CM, Guttridge B, Hall SM, Rowe B, Kleanthous H. Haemolytic uraemic syndrome in the British Isles 1985–8: association with verocytotoxin producing *Escherichia coli*. Part 1. Clinical and epidemiological aspects. *Arch Dis Child* 1990; 65: 716–721
- Petit RM. Thrombotic thrombocytopenic purpura; a thirty year review. *Semin Thromb Hemost* 1980; 6: 350–355
- Bell WR, Hayden GB, Ness PM, Kickler TS. Improved survival in thrombotic thrombocytopenic purpura-hemolytic uremic syndrome. *N Engl J Med* 1991; 325: 398–403
- Conlon PJ, Howell DN, Macik G, Kovalik EC, Smith SR. The renal manifestations and outcome of thrombotic thrombocytopenic purpura/hemolytic uremic syndrome. *Nephrol Dial Transplant* (in press)
- Nissenson AR, Port FK. Outcome of end-stage renal disease in patients with rare causes of renal failure. III systemic/vascular disorders. *Q J Med* 1990; 74: 63–74
- van den Berg-Wolf MG, Kooite AMM, Weening JJ. Recurrent hemolytic uremic syndrome in a renal transplant recipient and review of the Leiden experience. *Transplantation* 1987; 45:248–251
- Bassani CE, Ferraris J, Gianantonio CA, Ruiz S, Ramirez J. Renal transplantation in patients with classical hemolytic-uremic syndrome. *Pediatr Nephrol* 1991; 5: 607–611
- Eijgenraam FJ, Donckerwolcke RA, Monnens LAH, Proesmans W, Wolff ED, van Damme B. Renal transplantation in 20 children with hemolytic-uremic syndrome. *Clin Nephrol* 1990; 33: 87–93
- Schwarz A, Krause P, Offermann G, Keller F. Recurrent and *de novo* renal disease after kidney transplantation with or without cyclosporine A. *Am J Kidney Dis* 1991; 27: 524–531
- Doutrelepon JM, Abramowicz D, Florquin S *et al*. Early recurrence of hemolytic uremic syndrome in a renal transplant recipient during prophylactic OKT3 therapy. *Transplantation* 1992; 53: 1378–1379
- Hebert D, Sibley RK, Mauer SM. Recurrence of hemolytic uremic syndrome in renal transplant recipients. *Kidney Int* 1986; 30: S51–S58
- Herbert D, Kim E, Sibley RK, Mauer MS. Post-transplantation outcome of patients with hemolytic-uremic syndrome: update. *Pediatr Nephrol* 1991; 5: 162–167
- Karmali MA, Petric M, Lim C, Fleming PC, Arbus GS, Lior H. The association between idiopathic hemolytic uremic and infection by verocytotoxin-producing *Escherichia coli*. *J Infect Dis* 1985; 151: 775–782
- Crocker BP, Salmon DR. Pathology of the renal allograft. In: Tisher CC, Brenner BM, ed. *Renal Pathology*. Lippincott, Philadelphia, 1989, 1518–1586
- Hochstetler LA, Flanigan MJ, Lager DJ. Transplant-associated thrombotic microangiopathy: the role of IgG as initial therapy. *Am J Kidney Dis* 1994; 23: 444–450
- The Canada Apheresis Study Group. Comparison of plasma exchange with plasma infusion in the treatment of thrombotic thrombocytopenic purpura. *N Engl J Med* 1991; 325: 393–397
- Buturovic J, Kandus A, Malovrh M, Bren A,

- Drinovec J. Cyclosporine-associated hemolytic uremic syndrome in four renal allograft recipients: resolution without specific therapy. *Transplant Proc* 1990; 22: 1726–1727
21. Verpooten GA, Paulus GJ, Roels F, De Broe ME. *De novo* occurrence of hemolytic-uremic syndrome in a cyclosporine-treated renal allograft patient. *Transplant Proc* 1987; 19: 2943–2945
22. Chavers BM, Wells TG, Burke BA, Mauer SM. *De novo* hemolytic uremic syndrome following renal transplantation. *Pediatr Nephrol* 1989; 4: 62–64
23. Magalhaes RL, Braun WE, Straffon RA, Hoffman GC, Osborne G, Deodhar SD. Microangiopathic hemolytic anemia in renal allotransplantation. *Am J Med* 1975; 58: 862–868
24. Candinas O, Keusch G, Schlumpf R, Burger HR, Weder W, Largiader F. Prognostic factors of hemolytic uremic syndrome in renal allografts. *Transplant Proc* 1993; 25: 1041–1042
25. Lucca LJ, Ressurreicao F, Ferraz AS *et al.* *De novo* hemolytic uremia syndrome: a rare adverse effect in renal transplant recipients immunosuppressed with cyclosporine. *Transplant Proc* 1992; 24: 3098–3099
26. Byrnes JJ, Moake JL. Thrombotic thrombocytopenic purpura and hemolytic-uraemic syndrome: evolving concepts of pathogenesis and therapy. *Clin Haematol* 1986; 15: 413–442

Received for publication: 20.12.95

Accepted in revised form: 24.4.96